

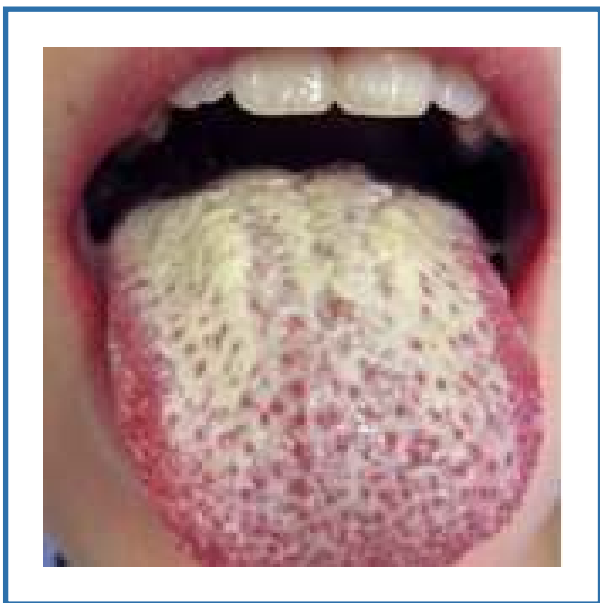
Dentistry

Oral manifestation of HIV – AIDS

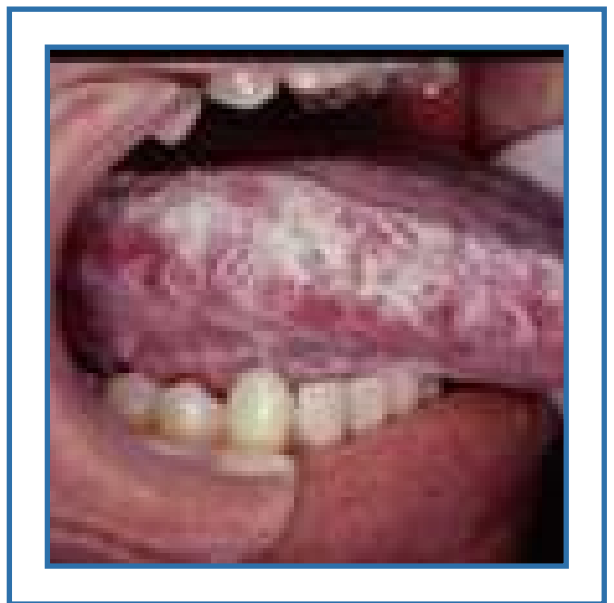Candidiasis and Oral hairy leukoplakia have consistently been found to be the most common oral lesions seen in adults with HIV diseases.

Candidiasis the most common fungal infection caused by *Candida albicans* that appears as a white superficial lesion and simple exfoliating cytology will identify the lesion.

Oral Hairy leukoplakia the most common viral infection appears as a asymptotic white patch with vertical corrugation most commonly on the lateral borders of the tongue.



Pseudomonas candidiasis



Oral hairy leukoplakia

*Dr. Kishor Kumar, MDS,
Tirupur*