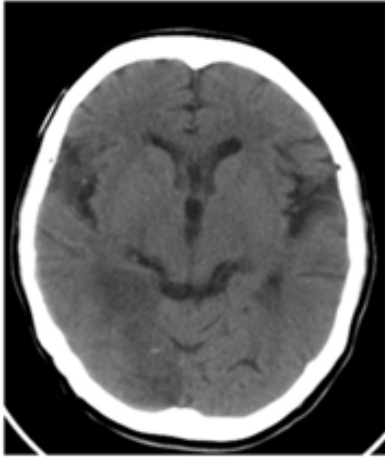


# Image Corner

## Image 3: CT brain – 60/male

Question: What is the clinical presentation of this patient?



## Answer for image 3:

This patient has infarct at right occipital region suggestive of PCA territory infarct; this patient presented with left homonymous hemianopia. Many times infarct may not be obvious and therefore such clinical information is crucial in guiding the Radiologist, to have a closer look of CT and if negative to go ahead with MRI DWI imaging.

***Dr. A Anbarasu, MD, DNB, Consultant Radiologist &  
Director Aran Diagnostic Imaging, Coimbatore.***