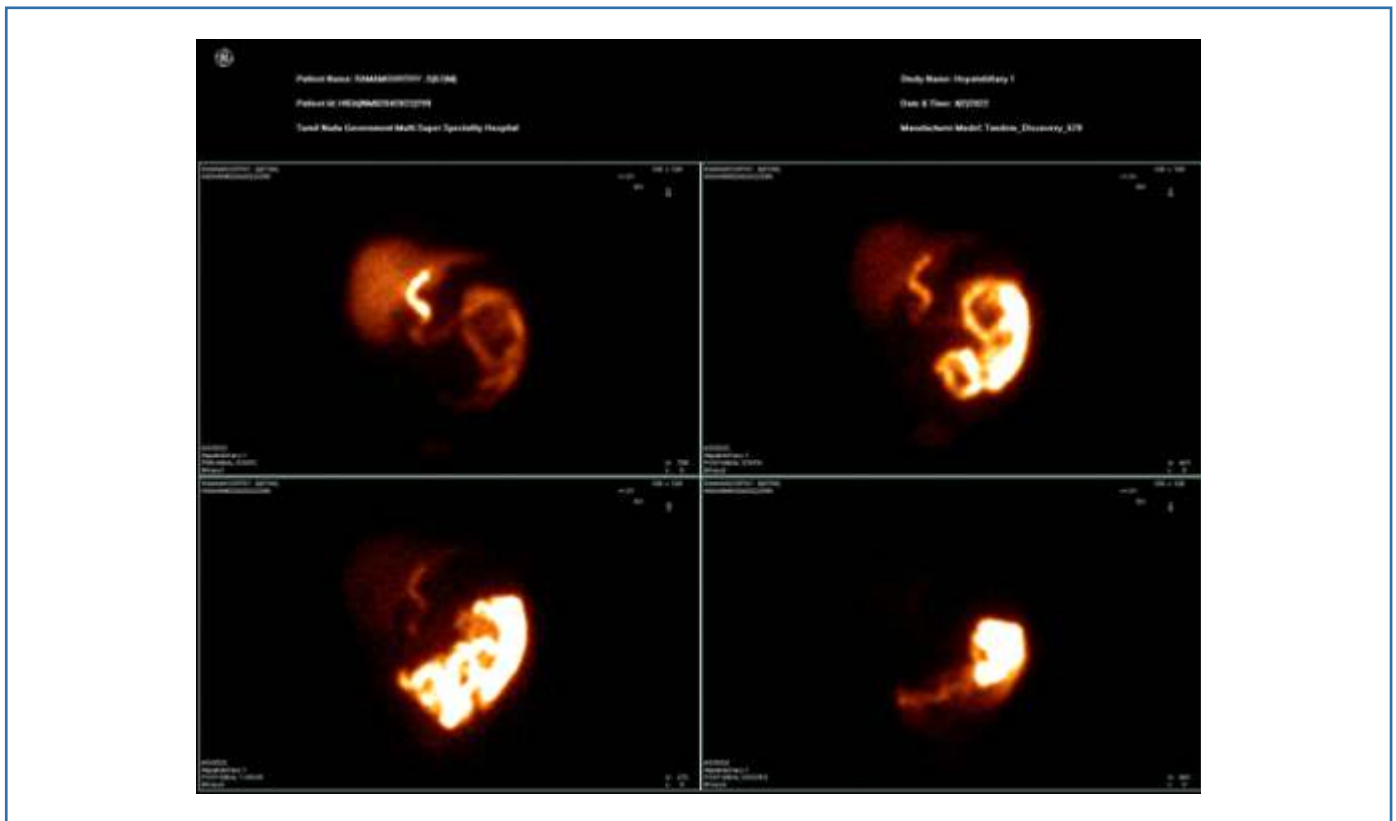


Nuclear Medicine

Acute Cholecystitis in ^{99m}Tc Mebrofenin Scan (Radioactive Technetium Mebrofenin Scan)

67 years old male had a vague pain in his abdomen for about 3 months. It becomes severe whenever he takes spicy foods. He is a diabetic with poor glycemic control. All his blood tests were normal – including his HbA1C levels. Ultrasound abdomen was unremarkable.



^{99m}Tc – Mebrofenin (tracer) Scan normal tracer flow in his liver parenchyma and biliary tracts. Delayed images – even after 4 hours tracer injection does not demonstrate Gall Bladder activity, although Ultrasound demonstrated Gall Bladder's presence. Absence of Gall Bladder in a Hepatobiliary scan is a classical of Acute Cholecystitis and this was confirmed after subsequent laparoscopic cholecystectomy.

Dr. E. Prabhu